

# Pressure injury

## Whara pēhanga



*The information in this guide is accurate to the best of our knowledge as of June 2023.*

### Definition

A **pressure injury** is localised damage to skin and underlying tissue that occurs as a result of pressure, friction or shearing forces. It can develop when pressure temporarily cuts off circulation and tissue dies. Most pressure injuries develop over bony prominences, especially the sacrum, hips and heels, but they can occur in other areas (EPUAP/NPIAP/PPPIA 2019).

### Why this is important

Pressure injuries are considered avoidable and have a significant impact on quality of life.

### Implications for kaumātua\*

It is important to give kaumātua and their whānau/family all the information they need to participate in pressure injury prevention and treatment. If they have a strong sense of pride or do not want to be a bother, kaumātua are less likely to ask for or accept help with pressure injury prevention. Whānau/family can suggest valuable, culturally informed interventions and help motivate kaumātua because they are invested in the outcome for their loved one.

Be aware of the concepts of tapu (sacred, prohibited, restricted) and noa (neutral, ordinary, unrestricted) if using pillows for positioning or pressure avoidance. People and their bodily fluids are considered tapu, and items that touch the body, particularly the head, carry tapu from the individual. Do not swap pillows and pillowcases that have been supporting the head with pillows that have been supporting other parts of the body. Doing so would be a breach of tapu and can have a significant negative impact on kaumātua and whānau/family spiritually and emotionally. See the *Guide for health professionals caring for kaumātua* | *Kupu arataki mō te manaaki kaumātua* for more information).

\* Kaumātua are individuals, and their connection with culture varies. This guide provides a starting point for a conversation about some key cultural concepts with kaumātua and their whānau/family. It is not an exhaustive list; nor does it apply to every person who identifies as Māori. It remains important to avoid assuming all concepts apply to everyone and to allow care to be person and whānau/family led.

## Assessment

- Assess all residents for risk of developing pressure injuries, using a standard risk assessment tool (see the policy of your own facility for the tool of choice). Tools differ in their diagnostic accuracy (Chou et al 2013).
- Implement a pressure injury prevention plan for every resident who is considered at risk of pressure injury.
- If a pressure injury develops, base wound care on wound assessment and the wound care goal (see the guides to *Wound assessment* | *Te aromatawai taotū* and *Wound care* | *Te maimoatanga o ngā taotū*). Reducing pressure, friction or shearing forces is the key to healing.

## Treatment

- Report pressure injuries in line with your facility's policy.
- To stage pressure injury, follow an agreed standard (European Pressure Ulcer Advisory Panel et al 2019) recommended by the Pan Pacific Pressure Injury Classification system (pictures on following pages) and use further resources [pppia.org/pppia-resources](http://pppia.org/pppia-resources).
- Pressure injuries in darker skin tones may be more difficult to identify, and this may lead to identification at a later stage (Oozageer Gunowa et al 2018). Specifically, stage 1 pressure injuries are unlikely to be reddened; however, damaged skin is likely to be different from surrounding skin in that it may be a different colour, firmer, softer, warmer or cooler than surrounding tissue. The area is also likely to be painful (Baker 2016).
- Use pressure-relieving equipment and techniques in line with your facility's policy.
- Chart and evaluate progress of the wound every 2 weeks.
- Treat the wound based on the wound care goal.
- Provide adequate pain management, nutrition and hydration. Manage continence and provide associated skin care (see the SSKIN poster available at: [www.nzwacs.org.nz/images/ppig/STOP\\_PI\\_2020\\_RESOURCES/3054\\_ACC\\_Pressure\\_Injuries\\_-\\_A3\\_Poster\\_FA\\_ONLINE\\_PRINT\\_SSKIN.pdf](http://www.nzwacs.org.nz/images/ppig/STOP_PI_2020_RESOURCES/3054_ACC_Pressure_Injuries_-_A3_Poster_FA_ONLINE_PRINT_SSKIN.pdf)).
- Refer high-risk wounds (stage 3 and above) to a specialist wound service and the responsible general practitioner or nurse practitioner.

## Care planning

The care plan includes specific pressure areas of care and holistic frailty management with the aim of maximising wellness and minimising the risk of developing further pressure injuries.

# PAN PACIFIC PRESSURE INJURY CLASSIFICATION SYSTEM FOR OLDER ADULTS

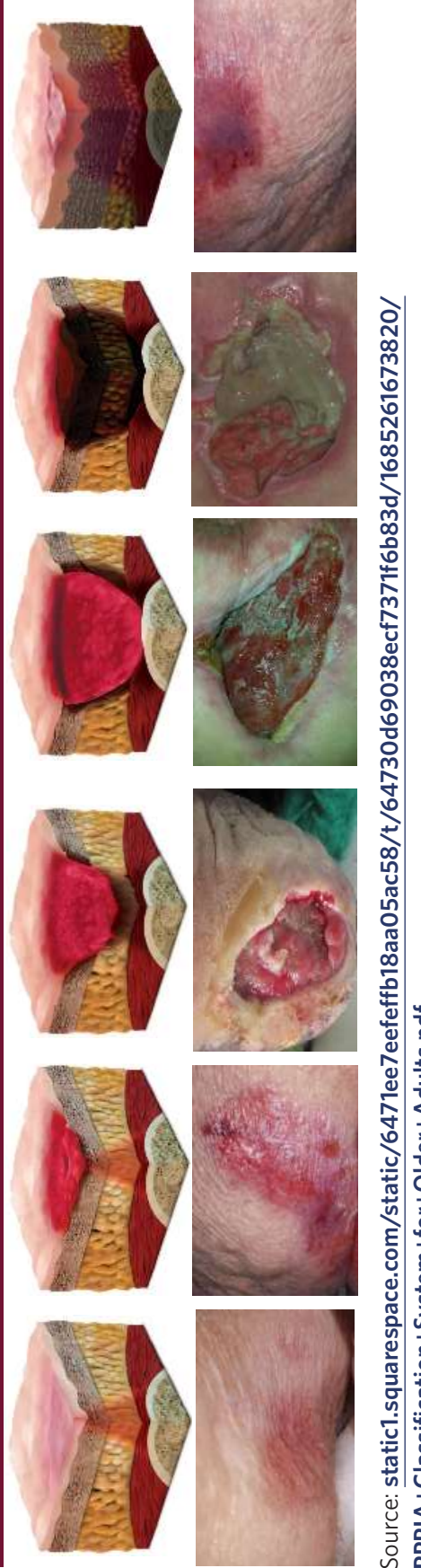

**Normal adult skin**

**Normal older skin**

Compared to the skin of younger adults, older skin has a thinner, more wrinkled epidermis and may appear paler or with pigmented (age) spots. Epidermis, dermis and subcutaneous fat layers are thinner. Skin moisture concentration is reduced and skin pH is raised in older adults.

Stage 1	Stage 2	Stage 3	Stage 4	Unstageable	Suspected Deep Tissue Injury
<p>Intact skin with non-blanchable redness of a localised area usually over bony prominences. Darkly pigmented skin may not have visible blanching; its colour may differ from the surrounding area. The area may be painful, firm, soft, warmer or cooler as compared to adjacent tissue. Stage 1 pressure injuries may be difficult to detect in older adults with darkly pigmented skin tone. May indicate 'at risk' older adults (a heralding sign of risk).</p>	<p>Partial thickness loss of dermis presenting as a shallow open ulcer with a red/pink wound bed, without slough. May also present as an intact or open/ruptured serum-filled blister. Presents as a shiny or dry shallow ulcer without slough or bruising (bruising indicates suspected deep tissue injury). Stage 2 pressure injuries should not be used to describe skin tears, tape burns, perineal dermatitis, maceration or excoriation.</p>	<p>Full thickness tissue loss. Subcutaneous fat may be visible, but bone, tendon or muscle are not exposed. Slough may be present but some parts of the wound bed. Often include undermining and tunnelling. The depth of a Stage 3 pressure injury varies by anatomical location. The bridge of nose, ear, occiput and malleolus do not have subcutaneous tissue and these pressure injuries can extend into muscle and/or supporting structures (e.g. fascia, tendon or joint capsule) making osteomyelitis possible. Exposed bone/tendon is visible or directly palpable.</p>	<p>Full thickness tissue loss in which the ulcer base is covered by slough (yellow, tan, gray, green or brown) and/or eschar (tan, brown or black) in the wound bed. Until enough slough and/or eschar is removed to expose the base of the wound, the true depth, (and therefore Stage) cannot be determined. Stable (dry, adherent, intact, no erythema or fluctuance) eschar on the heels serves as 'the body's natural (biological) cover' and should not be removed.</p>	<p>Purple or maroon localised area of discoloured intact skin or blood-filled blister due to damage of underlying soft tissue from pressure and/or shear. The area may be preceded by tissue that is painful, firm, mushy, boggy, warmer or cooler as compared to adjacent tissue. Deep tissue injury may be difficult to detect in older adults with dark skin tones. Evolution may include a thin blister over a dark wound bed. The wound may further evolve and be covered by thin eschar. Evolution may be rapid, exposing additional layers of tissue even with optimal treatment.</p>	



Source: [static1.squarespace.com/static/6471ee7eefbf18aa05ac58/t/64730d69038ecf7371f6b83d/1685261673820/PPPIA+Classification+System+for+Older+Adults.pdf](https://static1.squarespace.com/static/6471ee7eefbf18aa05ac58/t/64730d69038ecf7371f6b83d/1685261673820/PPPIA+Classification+System+for+Older+Adults.pdf)

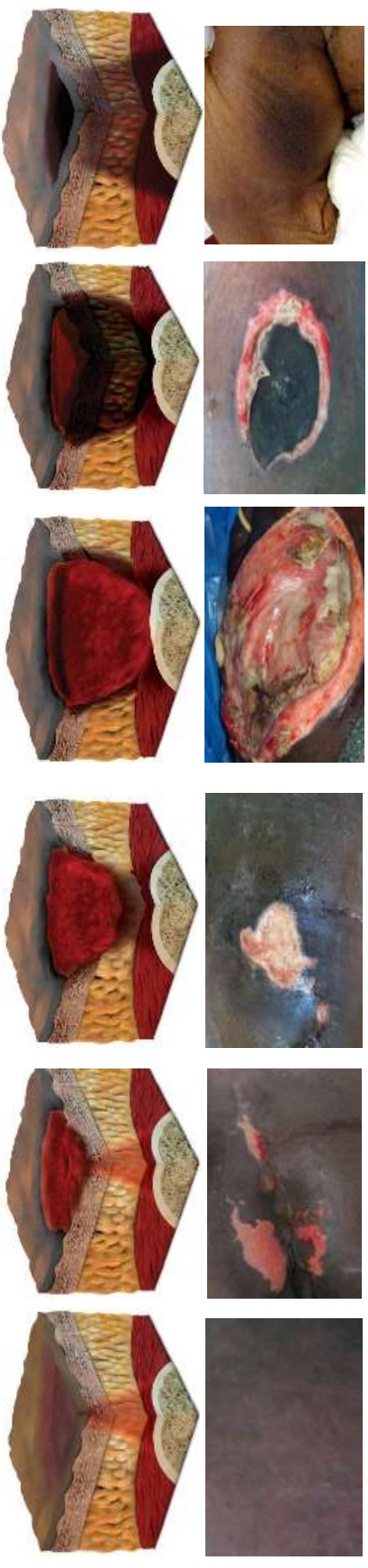
# PAN PACIFIC PRESSURE INJURY CLASSIFICATION SYSTEM FOR DARK SKIN TONES



**Text adapted from:** *International NPUAP/EPUAP Pressure Ulcer Classification System (2009,2014)* published in National Pressure Ulcer Advisory Panel (NPUAP), European Pressure Ulcer Advisory Panel (EPUAP), Pan Pacific Pressure Injury Alliance (PPPIA), Prevention and Treatment of Pressure Ulcers: Clinical Practice Guideline. 2014; Emily Haesler (Ed.) Cambridge Media: Osborne Park, WA. **3D graphics:** Owned by PPPIA. **Photos:** All photos courtesy Dr. Keryn Carville, used with permission. **Also available in this series:** PPPIA Classification System: Multicultural, PPPIA Classification System for Adults with Light Skin Tones, PPPIA Classification System for Neonates and Children, PPPIA Classification System for Asian Skin Tones, PPPIA Classification System for Older Adults.

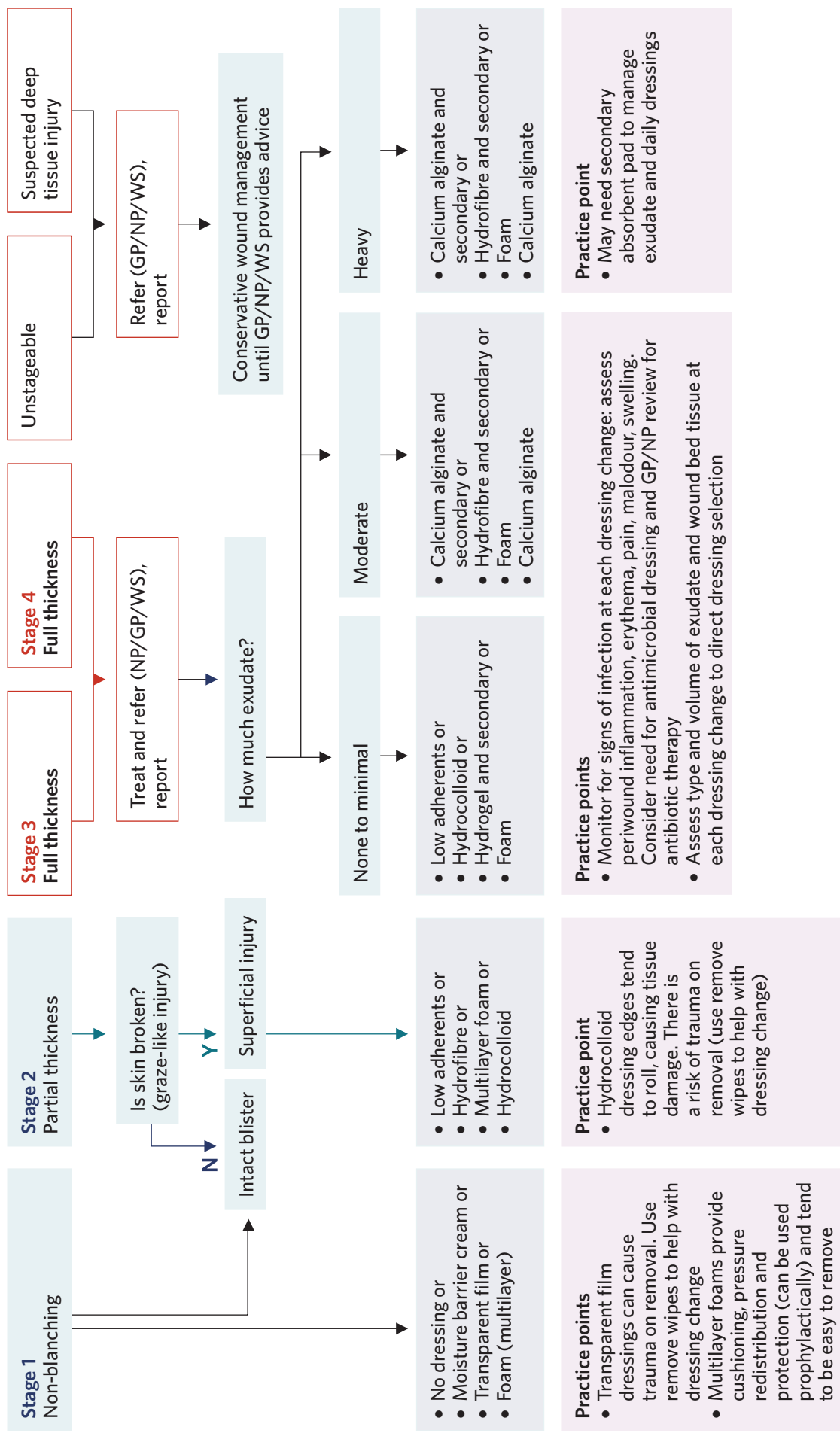
**More information and permission for use:** [www.pppia.org](http://www.pppia.org) © PPPIA 2020

Stage 1	Stage 2	Stage 3	Stage 4	Unstageable	Suspected Deep Tissue Injury
<p>Intact skin with non-blanchable redness of a localised area usually over bony prominences. Darkly pigmented skin may not have visible blanching; its colour may differ from the surrounding area. The area may be painful, firm, soft, warmer or cooler as compared to adjacent tissue. Stage 1 pressure injuries may be difficult to detect in individuals with darkly pigmented skin tone. May indicate 'at risk' individuals (a heralding sign of risk).</p>	<p>Partial thickness loss of dermis presenting as a shallow open ulcer with a red/pink wound bed, without slough. May also present as an intact or open/ruptured serum-filled blister. Presents as a shiny or dry shallow ulcer without slough or bruising (bruising indicates suspected deep tissue injury). Stage 2 pressure injuries should not be used to describe skin tears, tape burns, perineal dermatitis, maceration or excoriation.</p>	<p>Full thickness tissue loss. Subcutaneous fat may be visible, but bone, tendon or muscle are not exposed. Slough may be present but does not obscure depth of tissue loss. May include undermining and tunnelling. The depth of Stage 3 pressure injury varies by anatomical location. The bridge of nose, ear, occiput and malleolus do not have subcutaneous tissue and Stage 3 ulcers can be shallow. In contrast, areas of significant adiposity can develop extremely deep Stage 3 pressure injuries. Bone/tendon is not visible or directly palpable.</p>	<p>Full thickness tissue loss in which the ulcer base is covered by slough (yellow, tan, gray, green or brown) and/or eschar (tan, brown or black) in the wound bed. Until enough slough and/or eschar is removed to expose the base of the wound, the true depth, (and therefore Stage) cannot be determined. Stable (dry, adherent, intact without erythema or fluctuance) eschar on the heels serves as 'the body's natural (biological) cover' and should not be removed.</p>	<p>Full thickness tissue loss in which the ulcer base is covered by slough (yellow, tan, gray, green or brown) and/or eschar (tan, brown or black) in the wound bed. Until enough slough and/or eschar is removed to expose the base of the wound, the true depth, (and therefore Stage) cannot be determined. Stable (dry, adherent, intact without erythema or fluctuance) eschar on the heels serves as 'the body's natural (biological) cover' and should not be removed.</p>	<p>Purple or maroon localised area of discoloured intact skin or blood-filled blister due to damage of underlying soft tissue from pressure and/or shear. The area may be preceded by tissue that is painful, firm, mushy, boggy, warmer or cooler as compared to adjacent tissue. Deep tissue injury may be difficult to detect in individuals with dark skin tones. Evolution may include a thin blister over a dark wound bed. The wound may further evolve and be covered by thin eschar. Evolution may be rapid, exposing additional layers of tissue even with optimal treatment.</p>



Source: [static1.squarespace.com/static/6471ee7eefefb18aa05ac58/t/64730d1081a3ee02f9630144/1685261584745/PPPIA+Classification+System+for+Dark+Skin+Tones.pdf](https://static1.squarespace.com/static/6471ee7eefefb18aa05ac58/t/64730d1081a3ee02f9630144/1685261584745/PPPIA+Classification+System+for+Dark+Skin+Tones.pdf)

# Decision support



GP = general practitioner

NP = nurse practitioner

WS = wound specialist

'Report' means follow facility incident reporting guidelines.

## Further resources

Pan Pacific Pressure Injury Alliance (PPPIA) resources: [pppia.org/pppia-resources](http://pppia.org/pppia-resources)

Reproduction of the PPPIA classification system tools and flowcharts is permitted for all educational purposes **in the original formats (including acknowledgements and logos) available on the above website.**

Advisory Document for Wound Bed Preparation in New Zealand: [nzwcs.org.nz/images/publications/Wound\\_Bed\\_Preparation\\_June2020/NZWCSSoundBedPrepAdvisoryDoc2020.pdf](http://nzwcs.org.nz/images/publications/Wound_Bed_Preparation_June2020/NZWCSSoundBedPrepAdvisoryDoc2020.pdf)

SSKIN (Surface, Skin, Keep moving, Incontinence, Nutrition) poster: [www.nzwcs.org.nz/images/ppig/STOP\\_PI\\_2020\\_RESOURCES/3054\\_ACC\\_Pressure\\_Injuries\\_-\\_A3\\_Poster\\_FA\\_ONLINE\\_PRINT\\_SSKIN.pdf](http://www.nzwcs.org.nz/images/ppig/STOP_PI_2020_RESOURCES/3054_ACC_Pressure_Injuries_-_A3_Poster_FA_ONLINE_PRINT_SSKIN.pdf).

## References | Ngā tohutoro

Baker M. 2016. Detecting pressure damage in people with darkly pigmented skin. *Wound Essentials* 11(1): 28–31. URL: [www.wounds-uk.com/resources/details/wound-essentials-11-1-detecting-pressure-damage-in-people-with-darkly-pigmented-skin](http://www.wounds-uk.com/resources/details/wound-essentials-11-1-detecting-pressure-damage-in-people-with-darkly-pigmented-skin).

Chou R, Dana T, Bougatsos C, et al. 2013. Pressure ulcer risk assessment and prevention: a systematic comparative effectiveness review. *Annals of Internal Medicine*. DOI: 10.7326/0003-4819-159-1-201307020-00006.

European Pressure Ulcer Advisory Panel, National Pressure Injury Advisory Panel and Pan Pacific Pressure Injury Alliance (EPUAP/NPIAP/PPPIA). 2019. *Prevention and Treatment of Pressure Ulcers/Injuries: Clinical practice guideline. The International Guideline*. European Pressure Ulcer Advisory Panel, National Pressure Injury Advisory Panel and Pan Pacific Pressure Injury Alliance. URL: [internationalguideline.com/2019](http://internationalguideline.com/2019).

Oozageer Gunowa N, Hutchinson M, Brooke J, et al. 2018. Pressure injuries in people with darker skin tones: a literature review. *Journal of Clinical Nursing* 27: 3266–75. DOI: 10.1111/jocn.14062.